

DISTRACTION TECHNIQUES FOR LUMBAR PAIN

Inter-vertebral decompression—utilizing distraction techniques—widens disk spaces, lowers intradiscal pressure and promotes disk recovery.

by Alan E. Ottenstein, MD

At the dawn of the 21st century there are still a great many patients still suffering from common lumbar pain syndromes. Fortunately, unlike just a few decades ago, we now have many treatments to help these patients. These treatments run the gamut from doing “nothing” (eg. bed rest or passive modalities only) to doing “everything” (for example, open spinal surgery, discectomy, laminectomy, and/or interbody fusion). Choosing an appropriate treatment for a particular patient, however, is a complex process.

Unfortunately for all concerned, the

exact diagnosis is rarely clear cut. Using only the anatomical information found on imaging studies such as MRI and CT, the physician typically has a very low probability of making the proper etiological diagnosis for lumbar pain. The physician must also consider the patient’s complaint, abnormalities on neurological examination, limitations in activities of daily living, functional limitations, objective studies such as magnetic resonance imaging, EMG and nerve conduction studies, and other special studies that may be needed.

On top of all this, the physician must factor in the patient's preferences. The patient's lifestyle, personal preferences, prejudices, and philosophy toward medical interventions are the key final factors in determining which treatment will ultimately be given. Evaluation of any large group of patients—all having the same symptoms, findings, test results, diagnoses, and the same objective degree of disability—will reveal a wide range of prejudice in regards to suitable treatments. Some patients do not wish to take any medications whatsoever, while other patients may wish to use medications exclusively and not consider any other therapy. Still other patients will wish to have whatever therapy is available—no matter how aggressive and risky the treatment may be—as soon as possible. These patients are not unreasonable, they simply desire to do whatever may be necessary to get them back to “normal” as quickly as possible.

Background

We now have the benefit of many years of research to demonstrate that old treatments that we once thought were beneficial (for example passive physical therapy modalities and lumbar traction) are no longer believed to be useful or beneficial to patients suffering from serious lumbar spinal or neurological injuries. It has also become more widely appreciated that traditional lumbar surgery—with or without discectomy, laminectomy or interbody fusion, with or without installation of surgical hardware—can help some severely injured and disabled patients. However, surgery is not a panacea for most spinal problems. We now understand that there are great limitations to what surgery can accomplish. For example, open surgery performed for relief of pain alone rarely has a successful outcome. Surgeries performed for reasons of progressive neurological deficit, on the other hand, are more often successful. Recent years have seen a decrease in the percentage of patients undergoing these types of surgery as a result of more stringent selection criteria. As a result, a much higher proportion of these surgically treated patients now enjoy good outcomes.

Many of our patients that only a decade or two ago would have undergone open spinal surgery can now be helped by treatments that are far less invasive. These treatments include procedures performed

through a small incision less than one inch long such as microscopic discectomy. There are also many “less invasive” procedures performed with only the insertion of a large needle or catheter into the spine or perispinal tissues. These treatments include using a laser, rotors, clips, suction devices, or application of heat energy or radiofrequency energy to remove or alter part of the annulus or of the nucleus pulposus. Injection of agents that dissolve or chemically alter the nucleus or other spinal tissues have been used in this country and abroad for over two decades. These treatments have been well described in this and other publications.

...interventional but non-invasive therap(ies)... actively intervene in the disease process and help to bring about improvement in the patient's symptoms, and the disease itself—but do so without penetrating the patient's body.

Over the past decade a new procedure category has arisen: that of interventional but noninvasive therapy. Fortunately for today's patients, therapies in this class actively intervene in the disease process and help to bring about improvement in the patient's symptoms, and the disease itself—but do so without penetrating the patient's body. The most useful of these—and the most widely used at present—are the lumbar distraction techniques.

Pioneering Lumbar Distraction

The first lumbar distraction technique to enjoy widespread use was the vertebral

axial decompression technology (VAX-D®) developed in 1991 by Alan E. Dyer, PhD, MD, formerly a Deputy Minister of Health in Ontario, Canada. This VAX-D® device was shown to actually improve lumbar disk injuries and neurological symptoms in some patients. Despite a significant incidence of side effects, the procedure gained rapidly in popularity throughout Canada and the United States over the past decade because it could do what no other procedure had done before. This procedure could actually decrease the disability due to a herniated disk and actually affect the herniated disk without the need to physically invade the body.

A study conducted by Ramos and Martin in 1995 directly measured the effects of vertebral axial decompression on intradiscal pressure utilizing the VAX-D® and recorded significant reduction in pressure—up to -100 mm Hg—with applied tension in the upper range.¹

VAX-D® began its use in the United States in the early 1990s and was quite widespread by the late 1990s. However, many physicians became disenchanted with several of the drawbacks of the VAX-D®. The device transmitted a general force to the lumbar spine and could not individually select a vertebral level. The device required a patient's cooperation, and was dependent upon relaxation of the lumbar paravertebral muscles to allow distraction to take place while, at the same time, the therapy required the patient to maintain contraction of the shoulder girdles and cervical paraspinal muscles. Physiologically, this is a very difficult task to accomplish.

Despite some complications, VAX-D® therapy has remained popular throughout the United States due to the continuing benefit to many people with disabling spinal injuries—without the risks and costs associated with almost any surgical procedure. There are still many VAX-D® units in clinical practice.

Lumbar Distraction with IDD Therapy®

In the late 1990's a team of neurosurgeons, orthopaedic surgeons and other physicians headed by C. Norman Sheely, MD, developed a device that had most of the advantages of the VAX-D® but without the primary complications seen in VAX-D® therapy. This device called the DRS (distraction reduction stabilization) gained FDA clearance for use in the United States in January of 1998. The DRS

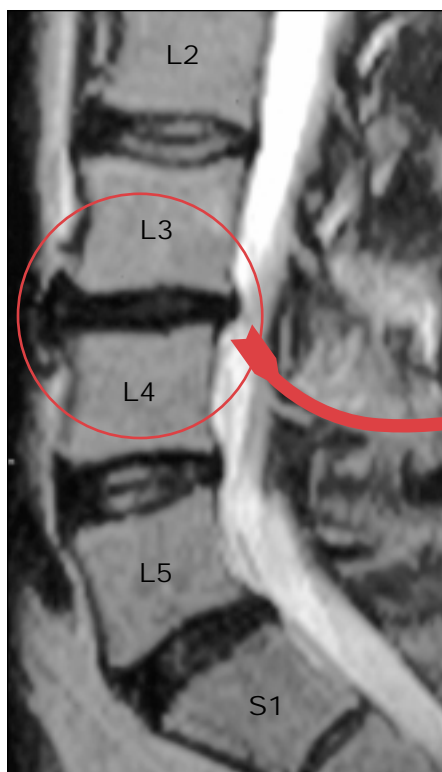


FIGURE 1A. Pre-treatment MRI (2/2/2000) of a patient with disk desiccation at L3-4 with rupture of the annulus.

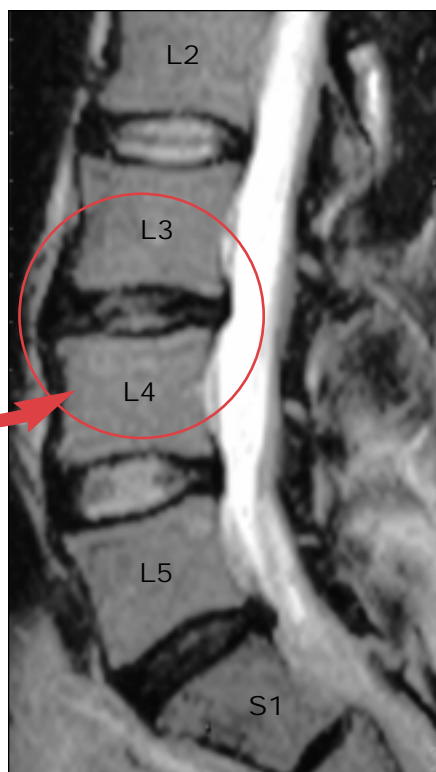


FIGURE 1B. Post-treatment MRI (3/20/2000) of the same patient after 11 sessions of treatment.

device, currently marketed as the SPINA System™ by Adagen Medical International, Inc., Atlanta, GA, has since rapidly gained market share and has replaced the use of VAX-D® in many physicians' offices because of increased efficacy and decreased degree of complications. This next generation technology utilizes internal disk decompression protocols known as IDD Therapy®.

Prospective double blind studies performed in the mid 1990s, comparing conventional lumbar traction with the distraction decompression techniques of IDD Therapy® in a series of patients, revealed that the latter was much more beneficial to patients than lumbar traction. The patients studied had been suffering from various lumbar pain syndromes including lumbar radiculopathy, lumbar disk degeneration and herniation, and lumbar facet syndrome.²

We believe that the DRS device, utilizing IDD Therapy®, is inherently more effective at accomplishing the spinal distraction than is the older VAX-D® technology, although we are not aware of any specific comparative studies. However, early experience with this device has shown that it is superior to the VAX-D®

treatment with decreased complications. In particular, usage of IDD Therapy® has so far demonstrated a noticeable improvement in both the theoretical and actual complication rate. This improved safety factor is one of the main reasons we usually suggest IDD Therapy® instead of VAX-D® if it's geographically available to the patient.

The precise technical description of the DRS device is beyond the scope of this article. What the DRS device with IDD Therapy® does is create and focus a distraction force at a given level of the lumbar spine through adjustment of the applied forces.³ The patient undergoing this treatment does not need to do anything to cooperate with the treatment other than relax. Unlike the VAX-D®, no force or strength on the part of the patient is needed. As a result, relaxation of the patient's muscles—especially lumbar paravertebral muscles can be accomplished.

Edward L. Eyerman, MD, wrote that DRS mechanical decompression distraction provided not only symptomatic improvement in patients with lumbar pain syndromes described above—but also improvement in magnetic resonance imaging findings from pre-treatment to post-

treatment.⁴ An actual before and after comparison of MRIs of one of the author's patients—presenting with a disk herniation at L3-4—demonstrated marked improvement after IDD Therapy® (see Figure 1). Herniation of the disk was reduced, disk height was increased and the disk was rehydrated after only 11 sessions during a 7-week period.

Treatment Protocols

The goal of the distraction treatment is significant relief of pain with restoration or improvement of physical spinal and neurological injury. The treatment protocols include:

1. Mechanical distraction to widen the intervertebral disk space resulting in decreased intradiscal pressure on nerves and blood vessels in the spine. The reduced pressure encourages shrinkage or a retraction of the herniated or bulged portion of the nucleus pulposus. The reduced pressure also allows improved diffusion of oxygen, nutrients, and hydration to the injured annulus and speeds healing.

2. Nutrition (foods and supplements) to provide the necessary precursors to provide building blocks necessary for disk repair.

3. Precautions to avoid re-injury during the healing phase.

4. Mobilization, daily stretching, and exercises to strengthen the muscles and prevent recurrence. This phase is initiated after the disk has been stabilized and healing is well under way.

Patients' Perspective

The treatment experiences on the part of patients have been overwhelming positive. The actual procedure is generally pain free, fast and safe. First the patient is custom-fitted to upper and lower spinal harnesses by a trained technologist. These harnesses and other applied devices help position the lumbar spine for comfort, as well as for proper alignment in the treatment process. Once fitted to the harnesses, the patient is slowly reclined to the treatment position. The therapist then applies distractive forces according to the patient's physical characteristics (ie. weight, body type) and directed to specific disk levels per the physician's specific orders. Through a series of treatments, each lasting twenty to thirty minutes, the patient's pain is quickly improved. Once patients begin to experi-

ence some pain relief and improved spinal function, they usually find the treatments comfortable, relaxing, and even enjoyable—many even look forward to their treatments.

Case Study 1: Neo

Neo is a 32-year-old white male computer programmer. He had been working for six years at his job and never missed a day of work. One day he was working at home and injured his back. The pain was so severe he could not get off the floor and lay on the floor for three weeks. Despite multiple visits to various physicians including treatment with medications, narcotics and epidural injections, the pain did not resolve. He remained essentially housebound and unable to stand, walk or sit for any appreciable period of time.

This patient was evaluated and found to have a herniated disk at L4-5, which appeared acute to sub-acute on MRI. His symptoms and clinical lumbar radiculopathy syndrome correlated with his examination and with his abnormal EMG and NCV studies. The patient underwent 20 DRS treatments using IDD Therapy®. Following the treatments, the patient noted marked improvement in his pain. He also noted improved activities of daily living and was able to return to work full-time with no restrictions. In follow-up, the patient was stable and remained improved.

Case Study 2: The Hospital Executive

The hospital executive is a 52-year-old president and CEO of a community hospital in Pennsylvania, about one hour from the author's offices. This individual noted onset of severe lumbar pain while lifting a heavy object. Evaluation at his hospital showed herniated disk posteriorly at L3-4. He underwent nine months of physical therapy with some slight improvement in his pain but no improvement in his disability. The patient was subsequently evaluated at our institution, and DRS with IDD Therapy® administered. Despite the 20 treatments that were advised, the patient felt well enough after 11 treatments that he did not wish further therapy. Upon discharge—after six weeks of IDD Therapy® consisting of only 11 of the 20 recommended treatments—he had much improved range of motion, decreased pain, and improved abilities to perform activities of daily living and activities at work. An MRI performed at the same time showed substantial improve-

ment in disk height and disk hydration as well as some improvement in disk herniation at the L3-4 level. The patient subsequently returned back to work and resumed all hobbies including actively hunting, fishing and boating, and has been stable. He continues to have improved pain, ADLs, and can still engage in all his favorite vocations and avocations.

Case Study 3: Great-grandma

An 89-year-old retired schoolteacher complained of severe low back pain with radiation to her legs. She was ultimately unable to follow her daily activities, which

The concept of using a distractive force to increase disk height and decrease the amount of herniation has been conceptually attractive to physicians for most of the last century.

she had enjoyed for many years. Her symptoms progressed to the point where she was unable to do any of the things that gave her the most pleasure. She liked to play bridge, but was unable to sit at the card table. She liked to entertain guests but was no longer able to cook, serve her guests, nor load her dishwasher without pain and so she ceased cooking and entertaining. She also became unable to tend her small garden.

This patient was evaluated and then underwent 20 DRS treatments utilizing IDD Therapy®. Following treatment, she noted improved freedom from pain and no

longer needed medications for pain. She noted improved ability to walk, bend and stoop. She also regained the ability to drive and regained the ability to walk while shopping, both in the grocery store and in the mall. A follow-up MRI study showed improvement in disk hydration and height. Follow up evaluation revealed that she had again been happily gardening, playing bridge, shopping, cooking, and entertaining friends at her home.

Discussion

The concept of using a distractive force to increase disk height and decrease the amount of herniation has been conceptually attractive to physicians for most of the last century. Unfortunately, attempts with various treatments and devices over the past 100 years have yielded no significant benefit to patients from lumbar traction. The current consensus of most physicians specializing in spine care and back pain organizations, and the conclusion of the U.S. Agency for Health Care Policy and Research (AHCPR) in a 1994 report on treatments for lumbar pain,⁵ was that lumbar traction was of no use in the treatment of the lumbar pain syndrome. We now know that lumbar traction does not benefit most patients—furthermore, we now understand why lumbar traction does not work.

Not only is lumbar traction ineffective in treating lumbar pain, but it can actually increase intradiscal pressure through a variety of mechanisms. These mechanisms include promoting a reflex co-contraction of lumbar paraspinal muscles. This contraction increases the axial load on the local disk segments and promotes increased intradiscal pressure. This increases the pressure on the annulus and may worsen an existing herniation, and/or raise the pressure enough to cause a new herniation.

Studies over the past decade have demonstrated that the new spinal distraction techniques discussed here, including VAX-D® and DRS with IDD Therapy®, are not traction. These new techniques work in an altogether different way than traction and, more importantly, they are effective—whereas lumbar traction is not. In recognition of this distinction, the United States government awarded a second level HCPCS code to VAX-D® effective January 1, 2000 to differentiate this effective treatment from the older, non-effective treatments—namely, lumbar

traction. The prospective double blind study published by Dr. Shealy demonstrated the effectiveness of distraction techniques for disk injury, herniation, and degeneration as well as for lumbar facet syndrome.²

Conclusion

These distraction devices are gaining market share in physician's offices—and for good reason. DRS with IDD Therapy[®] and the older VAX-D[®] treatments are part of the continuum in available treatments—from simple physical therapy and exercise to interventional surgery. As the above case studies demonstrate, distraction treatments that provide internal disk decompression have proven to be of very real benefit to these different patients, despite the differences in ages and pathologies. We have not yet determined all of the different pathologies that are amenable to treatment by this technology. We recommend at this time that physicians using this technology restrict their treatments to the FDA approved indications. This technology is currently cleared by the FDA as being safe and effective for

conditions and injuries producing spinal pain—including disk herniations, disk bulges, disk damage, disk degeneration, and facet syndrome. There is interest in using these therapies for other conditions and investigations are currently underway. We do not use this technology for simple back pain at this time, nor do we use DRS with IDD Therapy[®] for spinal strains or sprains alone. The IDD Therapy[®] appears most beneficial to patients with disk or facet joint pain, with or without accompanying lumbar and/or sacral radicular irritation.

While we have come to appreciate that passive physical therapy is not considered to be of long term benefit in most patients with lumbar spine syndromes—active physical therapy, exercise and stretching, and aerobic and other exercises undergone with the patient's cooperation are quite beneficial indeed. We believe that after an acute injury is properly treated and healed, a commitment to the appropriate exercises and simple lifestyle changes can give our patients a good chance of life-long freedom from a recurrence of spinal symptoms and disability. ■

Alan E. Ottenstein, MD, specializes in the treatment of neurological pain at Lawrenceville Neurology Associates, Lawrenceville, New Jersey, and at the Neurology Pain Center in Hamilton Township, NJ. Dr. Ottenstein is president of the Neurological Association of New Jersey. He may be contacted at 609-896-3100; www.LNA.neurohub.net

References

1. Ramos G and Martin W. Effects of vertebral axial decompression on intradiscal pressure. *J Neurosurg.* June 1995. 82(6):1095.
2. Shealy CN and Borgmeyer V. Decompression, Reduction, and Stabilization of the Lumbar Spine: A Cost-Effective Treatment for Lumbosacral Pain. *American Journal of Pain Management.* 1997. 7:63-65.
3. Shealy CN and Leroy PL. Chapter 20: New Concepts in Back Pain Management, Decompression, Reduction, Stabilization. *Pain Management: A Practical Guide for Clinicians. Volume 1.* St. Lucie Press. Boca Raton, FL. 1998.
4. Eyerman EL. *Simple Pelvic Traction Gives Inconsistent Relief to Herniated Lumbar Disc Sufferers.* Paper Presented To The American Society Of Neuroimaging. Orlando Florida, 2-26-98 and printed in *Journal of Neuroimaging.* June 1998
5. *Acute Low Back Pain Problems in Adults: Assessment and Treatment.* Quick Reference Guide for Clinicians. Clinical Practice Guideline #14. U.S. Agency for Health Care Policy and Research. 1994

PUBLISHERS PRESS DROP IN AD

Pearson Assessment